

Normal neurodevelopmental outcome despite severe and early extensive encephalomalacia: plasticity, repair or magic?

MYRIAM BICKLE GRAZ¹ | MARYLINE MONNIER¹ | LETIZIA VON LAER TSCHUDIN² | ANITA C TRUTTMANN³

1 Follow-up Unit, Department of Pediatrics, University Hospital Center and University of Lausanne, Lausanne; **2** Rehabilitation Center, University Children's Hospital Zurich, Affoltern; **3** Clinic of Neonatology, Department of Pediatrics, University Hospital Center and University of Lausanne, Lausanne, Switzerland.

Correspondence to Dr Myriam Bickle Graz, Follow-up Unit, Department of Pediatrics, University Hospital Lausanne, Lausanne, Switzerland.
Accepted for publication 22nd May 2013.

A male born at 26 weeks' gestation was seen for neurodevelopmental assessment at 4 years. His neonatal history was marked by the diagnosis of large subcortical cysts located in the left frontal and bilateral parietal regions, which was thought to carry a bad prognosis (Fig. 1a–c). Charts were carefully reviewed, specifically looking for hypocapnia, hypotension, and hypoglycaemia. Despite extensive investigations, no aetiology for this severe and atypical encephalomalacia was found.

He was born after a Caesarian section for chorioamnionitis with a birthweight of 815 grammes and APGAR scores were 1/3/4. The infant was treated for respiratory

distress syndrome, extubated on day 6, reintubated on day 11 for severe bradycardia/apnea, and then on mechanical ventilation until day 25 because of a symptomatic ductus arteriosus, surgically ligated on day 14. He stayed on nasal continuous positive airway pressure until day 93. Because of histological chorioamnionitis and despite negative cultures, antibiotics were given for 13 days.

Cranial ultrasounds showed right-sided grade II hemorrhage according to Papile et al.¹ on day 4, followed by moderate ventricular dilatation since day 14. Cysts became visible after day 35, 3 weeks after uneventful patent ductus arteriosus closure, in an atypical distribution, not commu-

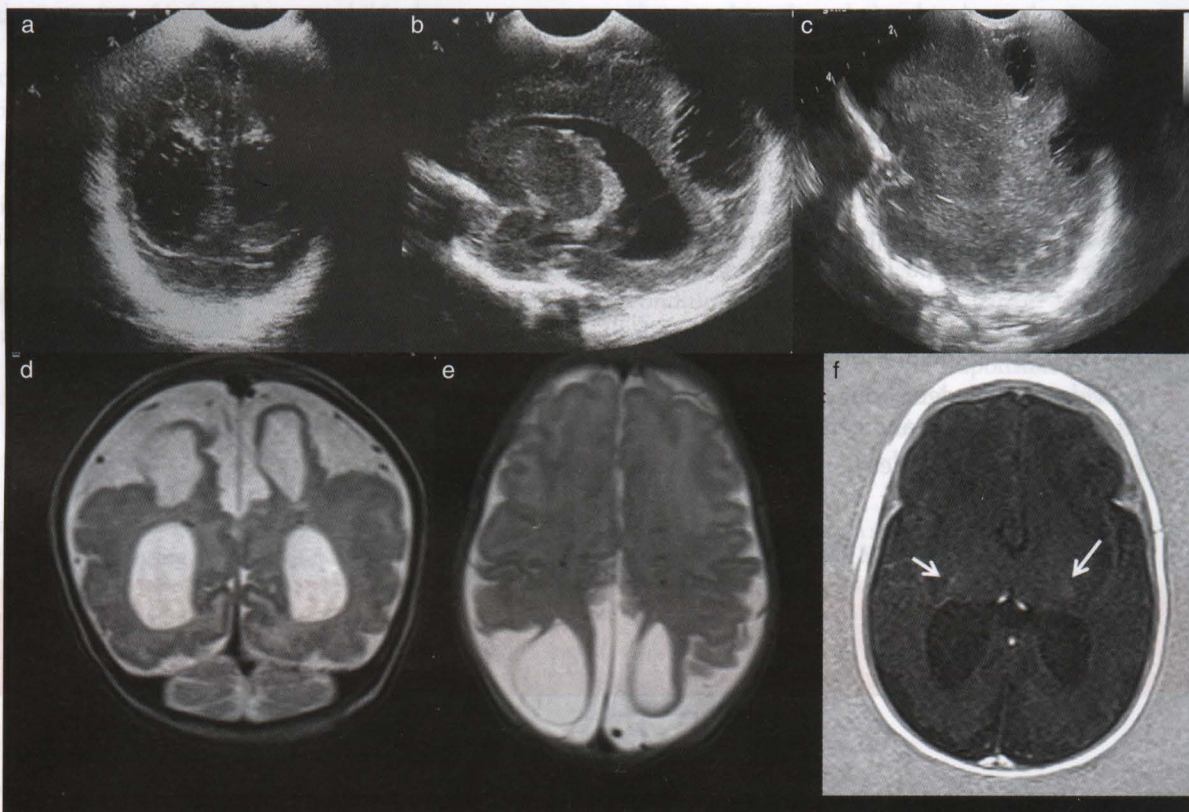


Figure 1: Cranial ultrasound day 35, showing the large multiple subcortical and cortical cysts on the (a) coronal and (b–c) right side sagittal views. Brain magnetic resonance imaging at term equivalent age, three Tesla Scanner, Verio: T2-weighted images showing extensive bilateral parietal subcortical and cortical cysts on (d) coronal, (e) transverse, and also frontal (not shown here) and transverse inversion recovery showing slight ventricular dilatation and (f) weak signal of the posterior limb of the internal capsula (white arrows).

nicating with the ventricles. On magnetic resonance imaging performed at term equivalent age (Fig. 1d-f), the cysts diminished in size; myelination and spectroscopy were considered normal. Follow-up at the age of 46 months revealed slightly delayed motor milestones and clumsiness, mild generalized hypotonia, normal vision and hearing, and microcephaly; occupational therapy was prescribed. Testing with the Wechsler Preschool and Primary Scale of Intelligence, Third Edition (median 100, SD 15) showed

unexpectedly normal and homogeneous cognitive capacities, (verbal index=96, perceptive=95, intelligence quotient=95, language=91). Further follow-up remains warranted.

Preterm neonates with atypical extensive brain lesions may have a favorable outcome. Few such cases are reported in the literature,² and counselling of the parents in these situations remains challenging.

REFERENCES

1. Papile LA, Burstein J, Burstein R, Koffler H. Incidence and evolution of subependymal and intraventricular hemorrhage: a study of infants with birth weights less than 1,500 gm. *J Pediatr* 1978; **92**: 529-34.
2. Govaert P, De Vries Linda S. An Atlas of Neonatal Brain Sonography, 2nd Edition Clinics in Developmental Medicine No. 182-183. London: Mac Keith Press, 2010.

Mac Keith Press

www.mackeith.co.uk/icna.html

Acquired Brain Injury in the Fetus and Newborn

International Review of Child Neurology Series

Edited by **Michael Shevell** and **Steven Miller**

- Pragmatic 'bench to bedside' approach to the diagnosis and care of newborns with acquired brain injury
- Synthesis of present advances and state of the art reviews
- Comprehensive coverage from basic science to acute clinical care to outcomes in the preterm and term newborn

280 x 205mm / 340 pages / Hardback / October 2012 / 978-1-907655-02-9 / £125.00

T: 0800 243407 (FREE PHONE, UK ONLY) or +44 (0)1243 843294

F: +44 (0)1243 843296 / **E:** cs-books@wiley.co.uk

